



UNIVERSITÀ DEGLI STUDI  
DI PERUGIA

SCUOLA di  
SPECIALIZZAZIONE  
in CHIRURGIA TORACICA  
Direttore Prof. F. Puma

**CHIRURGIA TORACICA**  
Aziende Ospedaliere di Perugia e Terni

---

---

---

---

---

---

---

---

## LE SINDROMI MEDIASTINICHE

Prof. Francesco Puma

---

---

---

---

---

---

---

---

Quadri clinici correlati a  
fenomeni di compressione  
e/o infiltrazione degli organi  
mediastinici

---

---

---

---

---

---

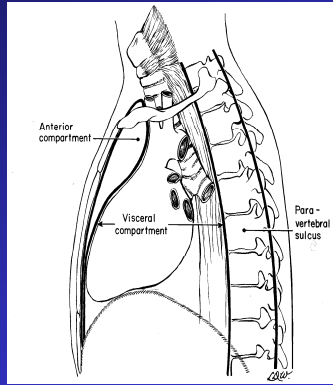
---

---

• Compartimento anteriore

• Compartimento viscerale

• Solchi paravertebrali



---

---

---

---

---

---

---

---

• **COMPARTIMENTO ANTERIORE**

Timoma, T. a cell. Germinali, linfoma, linfangioma, lipoma, fibroma, fibrosarcoma, cisti timica, adenoma paratiroideo, tiroide ectopica, adenopatie...

• **COMPARTIMENTO VISCERALE**

Cisti enterica, cisti neuroenterica, linfoma, cisti pleuropericardica, paraganglioma, feocromocitoma, adenopatie...

• **SOLCHI PARAVERTEBRALI**

Neurilemmoma-schwannoma, schwannoma maligno, neurofibroma, ganglioneuroma, neuroblastoma, paraganglioma, feocromocitoma, linfoma ...

---

---

---

---

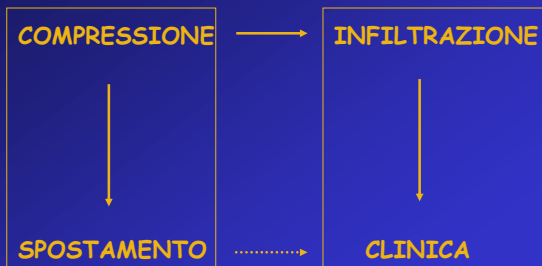
---

---

---

---

**FISIOPATOLOGIA**



---

---

---

---

---

---

---

---

## CLASSIFICAZIONE

- **S. respiratoria** (trachea)
- **S. digestiva** (esofago)
- **S. nervosa** (n. vago, n. ricorrente, n. frenico, catena del simpatico)
- **S. vascolare** (Vena cava superiore)

---

---

---

---

---

---

---

---

## S. Mediastinica respiratoria

- **SINTOMI**

tosse  
dispnea (preval. inspiratoria)  
emoftoe

- **Es. OBIETTIVO**

tirage  
cornage  
cianosi ?

---

---

---

---

---

---

---

---

## S. Mediastinica respiratoria

- **INDAGINI DIAGNOSTICHE**

Rx torace, TC torace, broncoscopia, PET

- **TRATTAMENTO**

medico  
endoscopico  
chirurgico

---

---

---

---

---

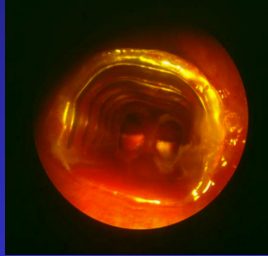
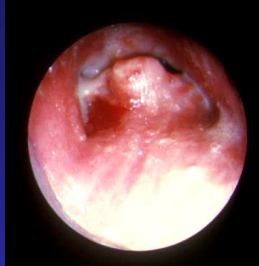---

---

---

## S. Mediastinica respiratoria

Trattamento endoscopico



---

---

---

---

---

---

---

---

## S. Mediastinica digestiva

- **SINTOMI**

disfagia ortodossa  
fenomeni "ab ingestis"  
rigurgito  
scialorrea

- **Es. OBIETTIVO**

calo ponderale

---

---

---

---

---

---

---

---

## S. Mediastinica digestiva

- **INDAGINI DIAGNOSTICHE**

esofagogramma, rx - TC torace, esofagoscopia, PET

- **TRATTAMENTO**

medico (NP e di supporto)  
endoscopico  
chirurgico

---

---

---

---

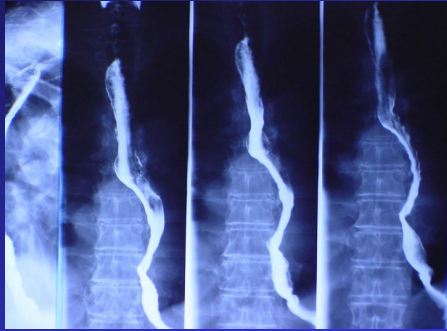
---

---

---

---

## S. Mediastinica digestiva



---

---

---

---

---

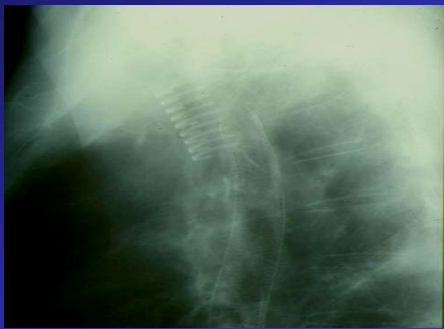
---

---

---

## S. Mediastinica digestiva

Trattamento endoscopico



---

---

---

---

---

---

---

---

## S. Mediastinica nervosa

Diversi nervi interessati:

- **N. LARINGEO INF:** disfonia
- **N. FRENICO:** singhiozzo, paralisi diaframmatica
- **N. VAGO:** tosse stizzosa, bradicardia
- **SIMPATICO:** S. di Claude-Bernard-Horner

---

---

---

---

---

---

---

---

## S. Mediastinica nervosa

- **INDAGINI DIAGNOSTICHE**

Rx e TC torace, laringoscopia, broncoscopia, PET

- **TRATTAMENTO**

Correlato alla etiologia

---

---

---

---

---

---

---

---

## SINDROME DELLA VENA CAVA SUPERIORE

---

---

---

---

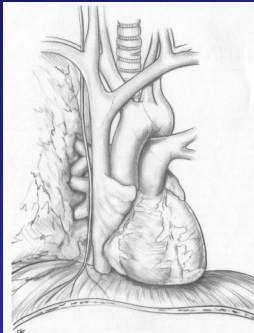
---

---

---

---

## Vena Cava Superiore: ANATOMIA



### DIMENSIONI

←→ : 7 cm Ø: 2 cm

### ORIGINE

Confluenza vv. anonime  
(I cartilagine costale ds)

### SBOCCO

Parete superiore atrio ds

### RAPPORTI

- Anteriormente: timo, polmone ds.
- Posteriormente: linfonodi 2R e 4R, arteria polmonare ds, vena polmonare sup ds.
- Medialmente: aorta ascendente.
- Lateralmente: polmone ds, nervo frenico ds.

---

---

---

---

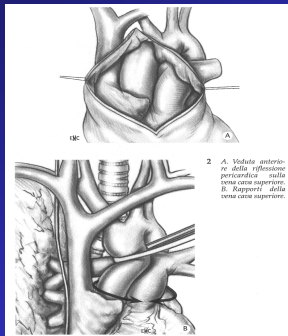
---

---

---

---

## Vena Cava Superiore: ANATOMIA



---

---

---

---

---

---

---

---

## S. Vena Cava Superiore: FISIOPATOLOGIA

SI VERIFICA PER OSTRUZIONE DELLA V. CAVA SUPERIORE O PER STENOSI  $> 3/5 \varnothing$

---

---

---

---

---

---

---

---

## S. Vena Cava Superiore: FISIOPATOLOGIA

SOPRA SBOCCO  
VENA AZYGOS

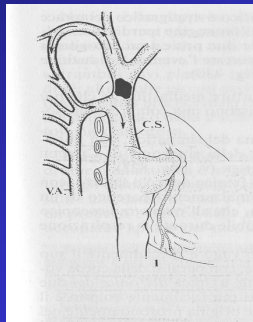
v. Succlavia

v. intercostale suprema

V. AZYGOS

V. CAVA SUP

CIRCOLO COLLATERALE  
PROFONDO



---

---

---

---

---

---

---

---

## S. Vena Cava Superiore: FISIOPATOLOGIA

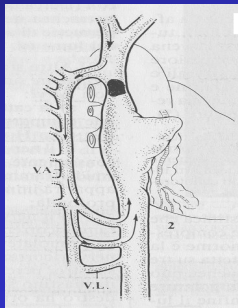
### SOTTO SBOCCO VENA AZYGOS

V. azygos

↓  
V. lombari

↓  
V. Cava Inferiore

CIRCOLO COLLATERALE  
PRESENTE




---

---

---

---

---

---

---

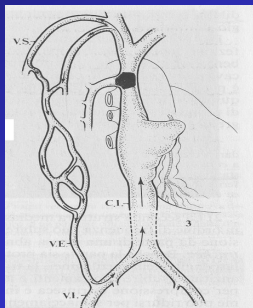
---

## S. Vena Cava Superiore: FISIOPATOLOGIA

### ALLO SBOCCO V. AZYGOS VV mammarie interne, epigastriche, intercostali

↓  
VENA CAVA INFERIORE

CIRCOLO COLLATERALE  
BENE EVIDENTE




---

---

---

---

---

---

---

---

## S. Vena Cava Superiore ETIOLOGIA

### TUMORI MALIGNI..... 95%

Cr. broncogeno (60%)

Linfomi

Metastasi

Timomi

### PATOL. BENIGNE.....5%

Mediastinite cronica fibrosante

Gozzo immerso

Trombosi

Aneurisma arco aortico

---

---

---

---

---

---

---

---



## S. Vena Cava Superiore

### SEGNi e SINTOMI

- Edema a mantellina
- Turgore venoso (aa. sup., giugulari)
- Edema palpebrale
- Rubrocianosi viso e padiglioni auricolari
- R.V.S.
- Dispnea
- Cefalea
- Ronzii
- Obnubilamento
- Associazione ad altre s. mediastiniche

---

---

---

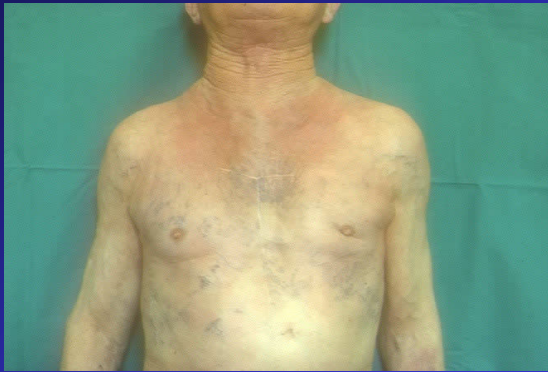---

---

---

---

---



---

---

---

---

---

---

---

---

## S. Vena Cava Superiore

### DIAGNOSI

- Rx torace
- Angio T.C. – R.M.N. torace
- PET
- Cavografia
- Broncoscopia
- FNAB (fine needle aspiration biopsy)
- Procedure endoscopiche mediastino

---

---

---

---

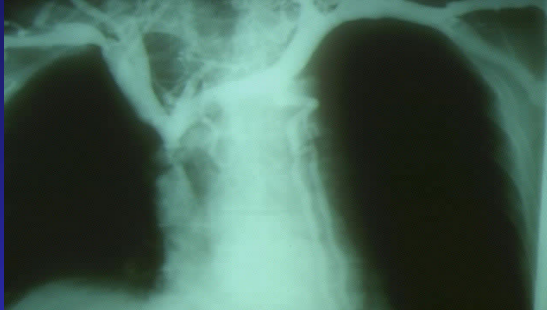
---

---

---

---

## S. Vena Cava Superiore



---

---

---

---

---

---

---

---

## S. Vena Cava Superiore

### TRATTAMENTO

- Di supporto {
  - ORTOSTASI
  - DIURETICI
  - STEROIDI
- Chemioterapia
- Radioterapia {
  - DOSE
  - FRAZIONAMENTO
  - CAMPO di IRRADIAZIONE
- Scoagulazione - Fibrinolisi
- Chirurgia (STENT, BY-PASS VENOSI)

---

---

---

---

---

---

---

---

## S. Vena Cava Superiore

### TRATTAMENTO

#### CHIRURGIA

- Stent endovascolari
- By-pass vascolare
  - REQUISITI
  - Gradiente pressorio
  - Letto di accoglimento (flusso)
  - Integrità intimale

---

---

---

---

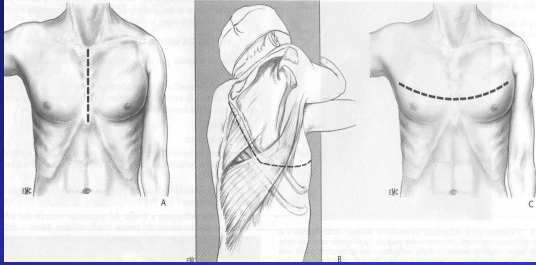
---

---

---

---

## S. Vena Cava Superiore



---

---

---

---

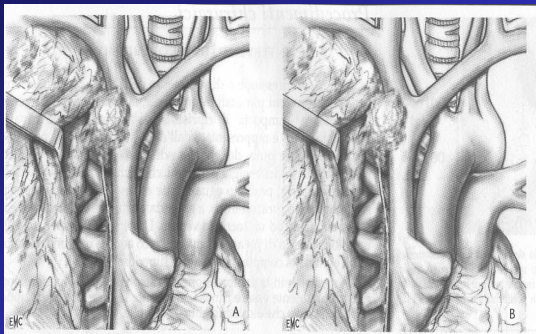
---

---

---

---

## S. Vena Cava Superiore



---

---

---

---

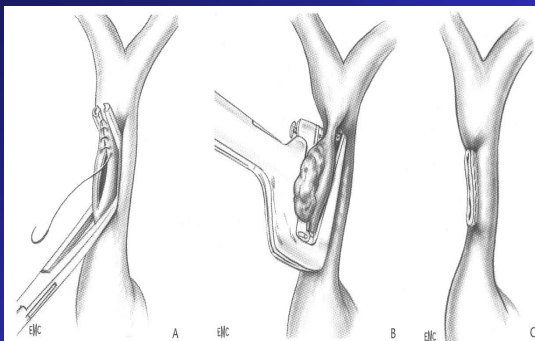
---

---

---

---

## S. Vena Cava Superiore



---

---

---

---

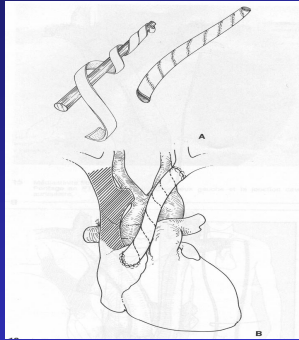
---

---

---

---

## S. Vena Cava Superiore



---

---

---

---

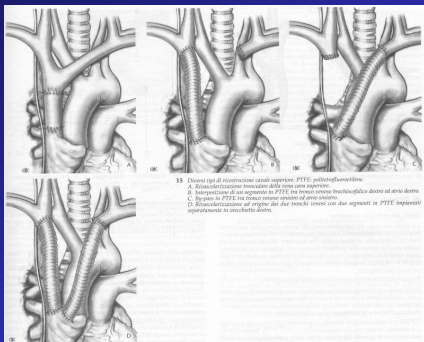
---

---

---

---

## S. Vena Cava Superiore



---

---

---

---

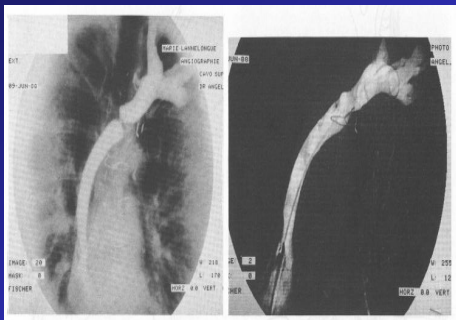
---

---

---

---

## S. Vena Cava Superiore



---

---

---

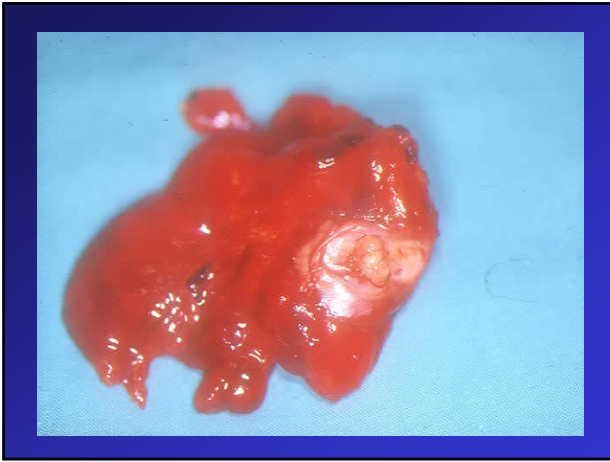---

---

---

---

---



---

---

---

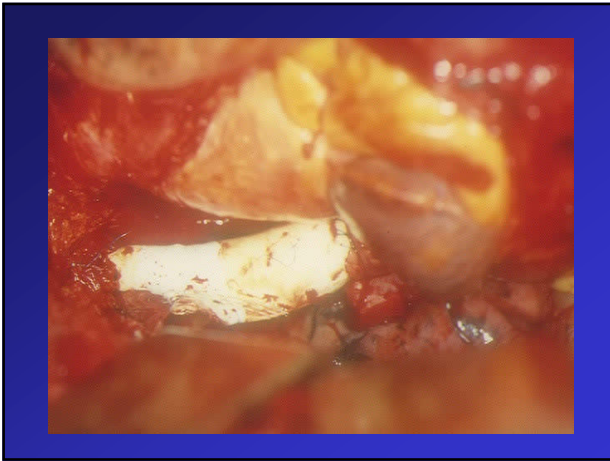
---

---

---

---

---



---

---

---

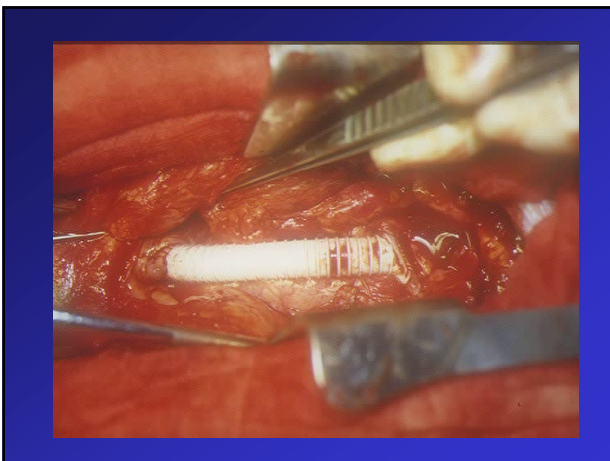
---

---

---

---

---



---

---

---

---

---

---

---

---